

## The effects of chloroform extract of *Psoralea corylifolia* seed on reproductive abilities of male albino rats

DABHADKAR DK<sup>1</sup>, ZADE VS<sup>\*1</sup>, DHORE MM<sup>2</sup> AND PATIL SS<sup>3</sup>

<sup>1</sup>Department of Zoology, Government Vidarbha Institute of Science and Humanities, Amravati- 444604, Maharashtra, India.

<sup>2</sup>Department of Botany, B.B. Arts, N. B. Commerce and B. P. Science College, Digra- 445 203, Maharashtra, India

<sup>3</sup>Director, Student Welfare, Sant Gadge Baba Amravati University, Amravati- 444 602, Maharashtra, India.

**\*Corresponding author:** Dr. Varsha S. Zade, Associate Professor, Department of Zoology, Government Vidarbha Institute of science and Humanities, Amravati. India.

Telephone: 0721- 2560170

Email, [zvarsha27@gmail.com](mailto:zvarsha27@gmail.com)

Article Received: 15/04/2013 | Article Revised: 18/04/2013 | Accepted: 15/06/2013

### ABSTRACT

The aim of the study is to evaluate the effect of the chloroform extract of *Psoralea corylifolia* on reproductive abilities of male albino rats. The chloroform extracts of *P. corylifolia* seeds at doses of 100, 200 and 400 mg/kg were administered for 21 days. The sperm count of experimental animal was determined. The effect of the extract on body weight, reproductive and vital organ weight were determined. The effective chloroform extract were further studied for its effect on hormonal assay and compared with the standard reference drug sildenafil citrate. Similarly adverse effects and acute toxicity of the extract were also evaluated. Oral administration of chloroform at doses of 100, 200 and 400 mg/kg were significantly increased the sperm count in experimental animal. There was significant increase in level of testosterone in the serum with increase in the LH and FSH concentration. The extract was also observed to be devoid of any adverse effects and acute toxicity. The results of the present study demonstrate that chloroform extract of *P. corylifolia* seed enhance sexual behaviour in male rats. It also thus provides a rationale for the traditional use of *P. corylifolia* as acclaimed aphrodisiac and for the management of male sexual disorders.

### KEY WORDS

Aphrodisiac,  
Herbal medicine,  
Male sexual  
behaviour,  
Male rat,  
*Psoralea corylifolia*,  
Seed

### INTRODUCTION

In the last few years, a marked decrease in the quality of semen has been reported (Carlsen *et al.*, 1992). Infertility is one of the major health problems in couples' lives; approximately 30% of couple's infertilities are due to male factors (Isidori *et al.*, 2006). Several conditions can interfere with spermatogenesis and reduce sperm quality and production. Many factors such as drug treatment, chemotherapy, toxins, air pollution, and insufficient vitamin intake may have harmful effects on spermatogenesis and the normal production of sperm (Mosher and Pratt, 1991). The classical approach to therapy of male infertility is via

spermatogenic drugs such as Clomiphene (Clomid).

However, prescription drugs like these are usually expensive, coupled with the possibility of adulteration as such. The gradual shift to herbal therapy with its attendant increasing acceptance, even among the elites, make the herbal practitioners lay claims to having the cure to a myriad of ailments, including male infertility, irrespective of the etiology of such diseases (Anthony *et al.*, 2006). Medicinal plants would be the best source to obtain a variety of drugs (Sharma *et al.*, 2009). World Health Organization estimates that up to 80 percent of people still rely mainly on traditional remedies such as herbs for medicines (Arun Kumar and Muthuselvam, 2009). *Psoralea corylifolia* (Linn) is a

medicinally important plant, belonging to family Fabaceae. The plant is also well recognized in Chinese and Indian folkloric medicine (Sarawat and Chand, 2001). Survey in the tribal belt of Melghat region (20° 51' to 21° 46' N and to 76° 38' to 77° 33' E) of Amravati district of Maharashtra state of India revealed that the *P. corylifolia* seeds is being consumed traditionally as an aphrodisiac. The seeds have been used for over many decades as traditional medicine. The seeds are used in indigenous medicine as laxative, aphrodisiac, anthelmintic, diuretic and diaphoretic in febrile conditions, and they have been specially recommended in the treatment of leucoderma, leprosy, psoriasis and inflammatory diseases of the skin and are prescribed both for oral administration and for local external application in the form of a paste or ointment (Latha and Panikkar, 1999).

The present work was undertaken to validate scientifically the spermatogenic role of *P. corylifolia* seeds as acclaimed by the traditional tribal user of Melghat region of Amravati district, Maharashtra. But to the best of our knowledge, there is no information in the open scientific literature that has substantiated or refuted the spermatogenic claims of *P. corylifolia* seeds in the folklore medicine.

## MATERIALS AND METHODS

### Collection of Plant Material:

The seeds *P. corylifolia* plant were collected from Melghat region of Amravati district during the flowering period of October to January, identified and authenticated by experts from Botanical Survey of India, Pune (Accession No. DD- 2).

### Procurement and Rearing of Experimental Animal:

Healthy wistar strain male albino rats of about two month old and weighing 200- 300 gm were procured from Sudhakar Rao Naik Institute of Pharmacy, Pusad (Maharashtra). The rats were housed in polypropylene cages and maintained under environmentally controlled room provided with a 12:12 hrs light and dark cycle approximately at 25 °C. They were fed on pellets (Trimurti Lab Feeds, Nagpur) and tap water *ad libitum*. The rats were allowed to acclimatize to laboratory environment for 15 days before experimentation.

All experimental protocols were subjected to the scrutinization and approval of Institutional Animal Ethics Committee [registration number 1060/ac/07 /CPCSEA (IAEC/7/2009)].

### Preparation of Extract:

The seeds of *P. corylifolia* were collected, shade dried, powdered and subjected to soxhlet extraction with chloroform. The extract was evaporated to near dryness on a water bath, weighed and kept at 4 °C in refrigerator until further use.

### Phytochemical Screening:

The presence of various plant constituents in the plant extract was determined by preliminary phytochemical screening as per Thimmaiah, (2004).

### Acute Toxicity Study:

Healthy male albino rats were starved for 3- 4 hr and subjected to acute toxicity studies as per Organization of Economic Co-operation and Development (OECD) guidelines No: 423 (OECD, 2001). They were divided into 4 groups of 6 animals each and kept singly in separate cages during the experiment. Group 1 represented the control group, which received 10 ml/kg of distilled water orally. Groups 2- 4 received suspension of chloroform seed extract of *P. corylifolia* orally at the doses of 1000, 2000 and 4000 mg/kg daily for 7 days respectively. The rats were observed continuously for 2 hrs for behavioural, neurological and autonomic profile, and for next 24 and 72 hrs for any lethality or death. No death was observed at highest dose (4000 mg/kg body weight) used.

### Effect on Sperm Count:

Healthy and sexually experienced male albino rats (200– 300 gm) that were showing brisk sexual activity were selected for the study. Sexually experienced male albino rats were divided into 3 groups of 6 animals each; Group 1 represented the control group, which received 10 ml/kg of distilled water orally. Group 2 received suspension of the chloroform extract of *P. corylifolia* orally at the dose 100, 200 and 400 mg/kg, daily for 21 days at 18:00 hrs. Group 3 served as standard and given suspension of sildenafil citrate orally at the dose of 5 mg/kg, 1 hr prior to the commencement of the experiment. After 21 days of treatment, the sperm

count was carried out by using Haemocytometer (Mukherjee and Kanai, 1988). Haemocytometer is generally used for RBC as well as WBC count. It is provided with the pipettes for the dilution of the blood samples and Neubauer's slide with special type of ruling. The counting is done in the ruled squares on the slide. The epididymis was removed and placed in a pre-chilled petriplate. 2 ml. of 0.9% saline was added to it and the cauda epididymis and testes were gently minced with the help of sharp razor. This sample was used for the sperm count. The sample was pipetted out with the help of pipette provided in the Haemocytometer. A clean and dry cover slip was kept on the Neubauer's ruling. The ruling was loaded with the sample by touching the tip of the pipette to the slide. The slide was kept on a bench for 2 min. to allow the sperms to settle down. The sperms were counted in four squares at the corner of the ruling covering an area of 4 sq. mm. under high power objective. The spermatozoa with head and tail were counted (Taylor *et al.*, 1985; WHO, 1999).

$$\text{Total Sperm count/ (epididymis, testes)} = \frac{\text{Sperm count}}{\times 0.1} \times 10$$

#### **Effect on Sexual and Vital Organ Weight:**

Healthy and sexually experienced male albino rats (200– 300 gm) that were showing brisk sexual activity were selected for the study. Sexually experienced male albino rats were divided into 3 groups of 6 animals each; Group 1 represented the control group, which received 10 ml/kg of distilled water orally. Group 2 received suspension of the chloroform extract of *P. corylifolia* orally at the dose 100, 200 and 400 mg/kg, daily for 21 days at 18:00 hr. Group 3 served as standard and was given suspension of sildenafil citrate orally at the dose of 5 mg/kg, daily 1 hr prior to the commencement of the experiment. After 21 days of treatment, all the control, standard and experimental groups of male rats were evaluated for their body weight. The animals were completely anaesthetized with anesthetic ether (Narsons Pharma), then sacrificed by cervical decapitation and testis, seminal vesicles, epididymis, vas-deference, penis and prostate glands along with vital organ like liver, kidney, adrenal gland, and spleen were carefully removed and weighed using 4- digital electronic balance (Mettler: Toledo AB 204- S). The relative organ weight of each organ were determined

(Relative organ weight= absolute organ weight/ body weight at sacrifice× 100) (Thakur and Dixit, 2006; 2007; Amini and Kamkar, 2005).

#### **Effect on Hormonal Profile:**

Healthy and Sexually experienced male albino rats were divided into 3 groups of 6 animals each; Group 1 represented the control group, which received 10 ml/kg of distilled water orally. Group 2 received suspension of the chloroform extract of *P. corylifolia* orally at the dose 100, 200 and 400 mg/kg, daily for 21 days at 18:00 hr. Group 3 served as standard and given suspension of sildenafil citrate orally at the dose of 5 mg/kg, 1 hr prior to the commencement of the experiment. After 21 days of treatment all the control, standard and experimental groups of male rats sera were analyzed for testosterone, luteinizing and follicle stimulating hormone level with AccuLite master CLIA VAST Enabled kit by Chemiluminescence immunoassay (CLIA) method with semi automated Chemiluminescence analyzer and autoplex- A processor for CLIA (Tietz, 1995; Uotila *et al.*, 1981).

#### **Histopathological Studies:**

Healthy and Sexually experienced male albino rats were divided into 3 groups of 6 animals each; Group 1 represented the control group, which received 10 ml/kg of distilled water orally. Group 2 received suspension of the chloroform extract of *P. corylifolia* orally at the dose 100, 200 and 400 mg/kg, daily for 21 days at 18:00 hr. Group 3 served as standard and given suspension of sildenafil citrate orally at the dose of 5 mg/kg, 1 hr prior to the commencement of the experiment. After 21 days of treatment, testis of animals belonging to control, experimental and standard groups were dissected out and immediately fixed in 10 % buffered neutral formalin solution. After fixation, tissues were embedded in paraffin, serial sections were cut at 5 µm, stained with hematoxylin and eosin, examined for histoarchitectural changes and photographed under Olympus BX51 light microscope (Kosif *et al.*, 2008).

#### **Statistical Analysis:**

All the data are expressed as mean ± S.E. Statistical analysis was done by Student's t-test and one way ANOVA (Mahajan, 1997).

## RESULT AND DISCUSSION

The seed of *P. corylifolia* has been in use by the tribals of Melghat region as a means of treating sexual inadequacy and stimulating sexual vigor even without recourse to the scientific validity of the claim. Hence this study was carried out to validate scientifically this tribal claim.

Preliminary phytochemical screening of the seed extract of *P. corylifolia* revealed the presence of alkaloids, flavonoids, steroids, phenolics, tannins and saponins whereas anthraquinone were not detected. The phytochemical screening can help to reveal the chemical constituent of the plant extract and the one that predominates over the other. It may also be used to search for bioactive agents as starting product used in the partial synthesis of some useful drugs (Harbone, 1998). It has been reported that steroid and saponin constituents found in the many plants possess fertility potentiating properties, and they useful in the treatment of impotence (Shukla and Khanuja, 2004). Saponins found primarily in the leaf *Tribulis terrestris* L. have been used as an aphrodisiac agent in both; Indian and Chinese traditional system of medicine (Singh and Gupta, 2011). The saponins may boost the level of testosterone in the body as well as trigger libido enhancing effect observed in this study (Gauthaman and Adaikan, 2008). The presence of flavonoids in the *P. corylifolia* extract which has been implicated to have a role in altering androgen levels may also be responsible for the enhanced male sexual behaviour in this study (Padashetty and Mishra, 2007). The alkaloids can also cause facilitation of sexual behaviour and has effect on sexual behaviour (Adimoelja, 2003). The improvement in sexual function demonstrated in the current study might thus be due to the presence of such compounds in *P. corylifolia* seed extracts. Further study are required to identify the active constitutes responsible for the sexual function improvement activities and the mechanism whereby these activities implanted are in progress.

Clinical toxicity symptoms such as respiratory distress, salivation, weight loss and change in appearance of hair as well as maternal mortality were not observed at any period of the experiment. Similarly no mortality and changes in the behavioural, neurological and autonomic profile were observed in treated groups of the rats up to

highest dose of 4000 mg/kg body weight. Hence one tenth of treated dose selected for present investigation. This suggested that short term use for this purpose is apparently safe. Similar finding was also observed by Tajuddin, *et al.* (2005), while working on ethanolic extract of *Myristica fragrans*.

Administration of chloroform seed extract of *P. corylifolia* at the dose of 100, 200 and 400 mg/kg, significantly increased the sperm concentration (sperm count) ( $P < 0.001$ ) in testes and epididymis as compared with control group. Similarly the standard group animal also showed significant increase in the sperm concentration (sperm count) ( $P < 0.001$ ) as compared with the control group (Table 1). The present results clearly indicate that administration of chloroform seed extract of *P. corylifolia* has good effect on spermatogenesis in rats. These results may be due to presence of flavonoids. Flavonoids are well known antioxidants that can ameliorate oxidative stress- related testicular impairments in animal tissues (El-Missiry, 1999; Ghosh *et al.*, 2002; Kujo, 2004). It also stimulates testicular androgenesis and is essential for testicular differentiation, integrity, and steroidogenic functions (Dawson *et al.*, 1990; Luck, 1995; Salem *et al.*, 2001). Our finding was also corroborating with the finding of Mukhallad *et al.*, (2009), while working on effect of *Nigella sativa* on spermatogenesis and fertility of male albino rats. The intragastric (i. g.) administration of chloroform seed extract of *P. corylifolia* at the dose of 100, 200 and 400 mg/kg, significantly caused an increase in body weight, when difference between initial and final weight body weight were compared with control. The relative weight of the reproductive organ like testes, caput segment of the epididymis, ventral prostate, seminal vesicle, penis and vas-deferens ( $P < 0.001$ ,  $P < 0.01$  and  $P < 0.05$ , respectively) increased significantly. Similarly, there was significant increase in the relative weight of the vital organs like liver, adrenal gland and spleen ( $P < 0.001$ ,  $P < 0.01$  and  $P < 0.05$ , respectively), when compared with control animal group (Table 2). The significant increase in the weight gain of reproductive and vital organs was also observed in standard group as compared to control. Genesis of steroids is one of the causes of increased body and sexual organ weight and an increase in these parameters could be regarded as a biological indicator for effectiveness of the plant extract in



improving the genesis of steroidal hormones (Thakur and Dixit, 2007). Since androgenic effect is attributable to testosterone levels in blood (Amini and Kamkar, 2005), it is likely that the plant extracts may have a role in testosterone secretion allowing better availability of hormone to gonads. Testosterone supplementation has previously been shown to improve sexual function and libido (Aversa and Fabbri, 2001), in addition to the intensity of orgasm and ejaculations which might also be expected to improve (Morels, 1996). Similar conclusion was recorded by Watcho, *et al*, (2005), while working on hexane extract of *Mondia whitei* on the reproductive organ of male rats.

The chloroform extracts *P. corylifolia* seed at the dose level of 100, 200 and 400 mg/kg body weight markedly influenced the hormonal level in extract treated animal. In the present investigation it was observed that testosterone ( $P < 0.001$ ) concentration significantly increased in extract treated animals. Similarly a significant increase in the serum concentration of luteinizing hormone (LH) ( $P < 0.001$ ) and follicle stimulating hormone (FSH) ( $P < 0.001$ ) was also recorded in extract treated animal as compared to control animal group. Similar observation was also recorded in standard group animal, when compared to control (Table 3). Studies in laboratory animals have implicated many components of plant extracts as possible bioactive agents responsible for increasing endogenous testosterone levels and enhancing male sexual behavior. These include steroids and saponins,

which may act as intermediaries in the steroidal pathway of androgen production. Saponins may bind to hormone receptors, resulting in conformational changes that can enhance the physiological functions of the hormone, or can bind to enzymes involved in the synthesis of such hormones, thus enhancing their production (Drewes *et al.*, 2003; Gauthaman and Adaikan, 2008). In addition, flavonoids have been implicated in altering androgen levels and may also be responsible for enhancing male sexual behavior by enhancing testosterone synthesis or by preventing its metabolic degradation (Ratnasooriya and Fernando, 2008; Yang *et al.*, 2004). Testosterone supplementation has previously been shown to improve sexual function and libido (Aversa and Fabbri, 2001), in addition to the intensity of orgasm and ejaculations which might also be expected to improve (Morels, 1996). In the present work the continued administration of the plant extract for 21 days at various doses which led to a significant increase in serum testosterone may be responsible for the marked effect on sexual behaviour indices of the male rats. FSH stimulates spermatogenesis and LH stimulates synthesis and release of testosterone. Testosterone causes an increased blood flow and stimulates the growth of the target tissues. Testosterone cause direct stimulation of spermatogenesis. Our results also show that there is increase in spermatogenesis and increase in weight of sexual organ in extract treated group in comparison to control group (Zarrow *et al.*, 1964).

**Table 1: Effect chloroform extract *P. corylifolia* seed on sperm concentration of male albino rats**

Treatment group	Doses (mg/kg body wt.)	Sperm Count (No. of sperm/ rat/ 10%)	
		Cauda epididymis	Testes
Group-I Control	Vehicle	41.62±2.47	6.45±0.33
Group- II Chloroform extract	100	44.5±1.77**	8.86±0.73*
	200	50±2.34***	9.53±0.48***
	400	56.66±2.78***	9.98±0.18***
Group-III Sildenafil citrate	5	49.64±1.58***	8.33±0.66**

Values in Mean± S.E. (Standard error), n=6, \* $P < 0.05$ , \*\* $P < 0.01$ , \*\*\* $P < 0.001$ , when compared with control, ns- non significant.

**Table 2: Effect of chloroform extract of *Psoralea corylifolia* seed on body weight, reproductive organ and vital organ weights of male albino rats**

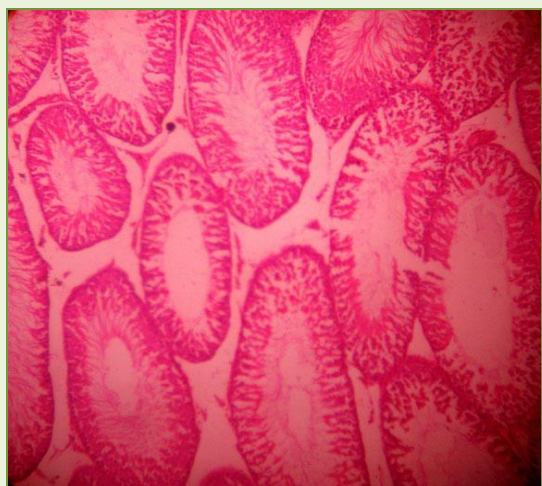Treatment Groups	Doses (mg/kg b. wt.)	Body weight (gm)		Relative organ weight (%)									
		Initial	Final	Testes	Epididymis	Seminal vesicle	Ventral prostate	Vas-Deferens	Penis	Liver	Kidney	Adrenal Gland	Spleen
Group- I	Vehicle	189.1±3.28	191.8±2.11	1.694±0.08	1.084±0.09	0.421±0.02	0.149±0.01	0.332±0.01	0.134±0.11	3.752±0.13	1.305±0.01	0.024±0.03	0.239±0.03
Group-II Chloroform extract	100	179.6±1.71	194.43±0.48**	1.583±0.68 <sup>ns</sup>	1.062±0.39 <sup>ns</sup>	0.318±0.02**	0.176±0.24***	0.311±0.05**	0.112±0.01**	3.469±0.26 <sup>ns</sup>	1.332±0.34 <sup>ns</sup>	0.025±0.02*	0.198±0.03***
	200	194.8±1.76	213±1.80***	1.826±0.70**	1.188±0.32***	0.417±0.04**	0.135±0.01 <sup>ns</sup>	0.345±0.02***	0.160±0.02***	3.020±0.40*	1.170±0.46**	0.025±0.01 <sup>ns</sup>	0.239±0.02***
	400	230.1±1.18	251±1.83***	1.583±0.84*	1.307±0.21***	0.498±0.07***	0.154±0.07*	0.354±0.04***	0.168±0.03***	3.951±0.60**	1.526±0.32***	0.024±0.02 <sup>ns</sup>	0.260±0.01***
Group- III Sildenafil citrate	5	196.6±2.11	198.66±5.67***	2.005±0.06***	1.328±0.13***	0.448±0.05**	0.184±0.01***	0.331±0.01 <sup>ns</sup>	0.139±0.05*	3.991±0.17***	1.342±0.1***	0.026±0.03**	0.185±0.01**

Values in Mean± S.E. (Standard error), n=6, \*P<0.05, \*\*P<0.01, \*\*\*P<0.001, when compared with control, ns- non significant.

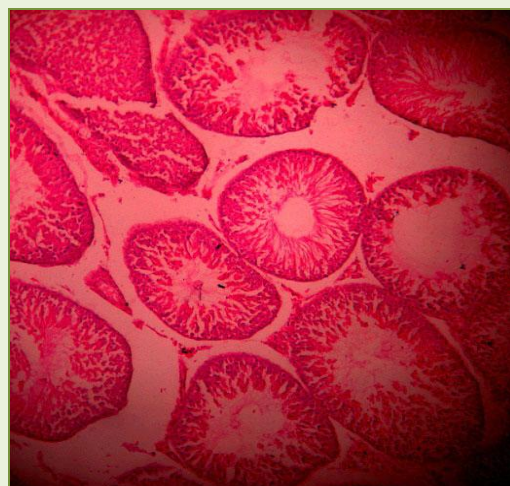**Table 3: Effect of chloroform seed extract of *P. corylifolia* on hormone profile in male rats**

Treatment group (doses, mg/kg body wt)	Group-I Control	Group-II Sildenafil citrate	Group-III Chloroform seed extract of <i>P. corylifolia</i>		
	Vehicle	5 mg/kg	100 mg/kg	200 mg/kg	400 mg/kg
Testosterone (ng/ml)	1.41±0.79	2.15±0.68*	2.69±0.42**	3.08±0.18***	3.34±0.11***
LH (ng/ml)	1.19±0.17	2.49±0.28**	2.23±0.33 <sup>ns</sup>	2.27±0.16*	3.42±0.67***
FSH (ng/ml)	17±1.36	20±0.77***	20.66±1.20**	21.7±0.98***	24.12±0.45***

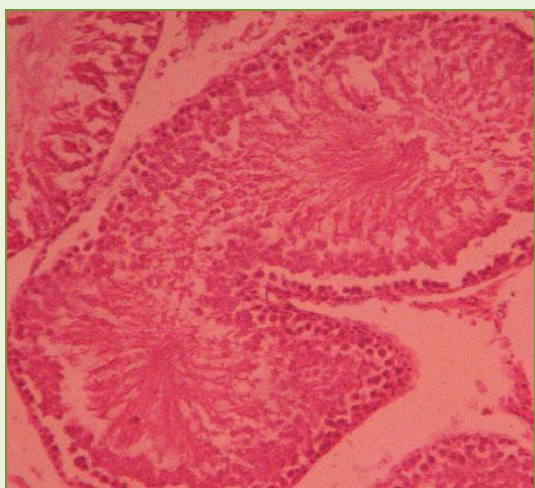
Values in Mean± S.E. (Standard error), n=6, \*P<0.05, \*\*P<0.01, \*\*\*P<0.001, when compared with control, ns- non significant.



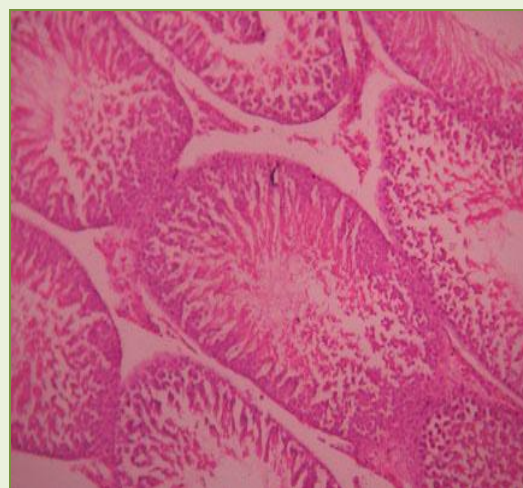
(a)



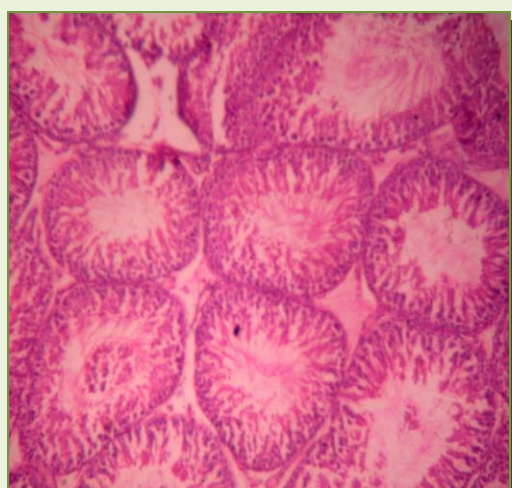
(b)



(c)



(d)



(e)

**Fig. 1:-Photomicrographs of testes tissue sections of rats**

**(a):** control rats showing normal testes architecture,

**(b):** treated with 5 mg/kg body wt. dose of Sildenafil citrate;

**(c):** treated with 100 mg/kg body wt. dose of chloroform extract of *P. corylifolia* seed;

**(d):** treated with 200 mg/kg body wt. dose of chloroform extract of *P. corylifolia* seed;

**(e):** treated with 400 mg/kg body wt. dose of chloroform extract of *P. corylifolia* seed. 100X]



The testis of control group animals showed normal histological texture. All stages of spermatogenesis were clearly observed viz. spermatogonia, spermatocytes, spermatid and spermatozoa, beside connective tissue, blood vessels, lymph ducts and leydig's cells were observable and distinct. The cuboidal germinal epithelium exhibited normal shape and size. Sertoli cells had many cytoplasmic processes which were normal in size.

Spermatozoa were embedded in the sertoli cells and showed normal cytoplasmic granulation. Leydig's cells had normal nuclear size. Luminal part of the tubule were normal in number with bundles of spermatozoa. Spermatozoa with long tail and small distinct head were more visible (Fig. 1a). The animal in the extract treated group showed pronounced effects in terms of testis weight and histological alterations. Since the weight and size of the testis was greater in extract treated groups almost all seminiferous tubules showed greater morphological difference in size (i.e. it showed increase in the size of seminiferous tubules). The solid packing of seminiferous tubule was quite evident as compared to control. Basement membrane was tightly bound with germinal epithelium. The lumen of seminiferous tubule was filled with bundles of spermatozoa. In some tubules, spermatids were found scattered amidst spermatozoa. The germinal epithelium cells appeared to be hyperactive. Large numbers of different cells at different stages of spermatogenesis were evident. Sertoli cells were enlarged, highly processed and rich in nutrients as evidenced by highly granulated cytoplasm. This was the normal response of the sertoli cells when they were in readiness for providing nutritional supplementation to large number of spermatozoa (Mujumdar, 1995). Almost all leydig cells showed hypertrophy with enlarged nucleus and darkly stained cytoplasm. A very clear view of leydig cells was seen in photomicrograph of different doses of chloroform extract treated groups. Increment in the volume of cells and nucleus was strongly suggestive of steroid synthesis under the direct or indirect influence of the drug. The blood vessels of testis were slightly dilated (Fig. 1c, 1d and 1e).

Histoarchitecture of sildenafil citrate treated groups also exhibited similar profile. The solid packing also suggests a supposed role of

testosterone in increasing the vascularisation of testicular tissue. Increased spermatogenesis was evident by high number of spermatozoa in seminiferous tubules and increase in spermatogenic elements as compared to control (Fig. 1b). This histoarchitectural evidence was the clear indication of confirming the spermatogenic efficacy of extracts of *P. corylifolia* seeds in male albino rats. The process of spermatogenesis and accessory reproductive organ function are androgen dependent. In present study the numbers of mature leydig cells as well as number of spermatocytes and spermatids were significantly increased, which reflect the increase of androgen level (Dym *et al.*, 1979). Similar finding were also reported, while working on spermatogenic effect of *Nigella sativa* (Mukhallad *et al.*, 2009), of *Curculigo orchoides* in male rats (Chauhan and Dixit, 2008).

## CONCLUSION

The present results confirm that the seeds *P. corylifolia* ingestion produce increased effects on fertility and reproductive system in adult male rat. It also lends support to the claims for traditional usage of *P. corylifolia* as a sexual function enhancing medicine. Thus, this study may prove to be an effective and safe alternative remedy in sexual disorders. Work is in progress on the isolation and characterization of the spermatogenic principle in the plant extract, the actual mechanism of action of the crude extract and bioactive agents.

## ACKNOWLEDGMENT

Authors are thankful to Department of Science and Technology, Government of India for funding the present work as a part of the Ph. D. program in the form of INSPIRE Fellowship. The authors are grateful to CPCSEA, Chennai, Ministry of Justice and Empowerment, Government of India and IAEC, Government Vidarbha Institute of Science and Humanities, Amravati (M.S) for giving the permission to do for doing the experimental work on rats.

## REFERENCES

- Adimoelja A (2003) Phytochemicals and the breakthrough of traditional herbs in the management of sexual dysfunctions. *International Journal of Andrology*, 23: 82- 84.



- Amini A and Kamkar F (2005) The effects of gossypol on spermatogenesis in NMRI mice. *Iranian Journal of Science and Technology Transfer*, 29: 123-133.
- Anthony BO, Oladipupo AL, Adedoyin KL, Tajuddin IA (2006) Phytochemistry and spermatogenic potentials of aqueous extract of *Cissus populnea* (Guill. And Per) stem bark. *The Science World Journal*, 6: 2140- 2146.
- Arunkumar S and Muthuselvam M (2009) Analysis of phytochemical constituents and antimicrobial activities of *Aloe vera* L. against clinical pathogens. *World Journal of Agricultural Science*, 5: 572-576.
- Aversa A and Fabbri A (2001) New oral agents for erectile dysfunction: what is changing in our practice? *Asian Journal of Andrology*, 3: 175- 179.
- Carlsen E, Giwercman A, Keiding N, Skakkeback NE (1992) Evidence for decreasing quality of semen during past 50 years. *BMJ*, 12:609- 613.
- Chauhan NS and Dixit VK (2008) Spermatogenic activity of rhizomes of *Curculigo orchoides* Gaertn in male rats. *International Journal Applied Research in Natural Products*, 1: 26- 31.
- Dawson EB, Harris WA, Powell SA (1990) Relationship between ascorbic acid and male fertility. *World Review of Nutrition Dietetics*, 62: 1- 26.
- Drewes SE, George J, Khan F (2003) Recent findings on natural products with erectile-dysfunction activity. *Phytochemistry*, 62:1019-1025.
- Dym MR, Raj HGM, Lin YC, Chemes HE, Kotitie NJ, Nayfeh SN, et al (1979) Is FSH required for maintenance of spermatogenesis in adult rats? *Journal of Reproductive and Fertility*, 1: 175- 181.
- El-Missiry MA (1999) Enhanced testicular antioxidant system by ascorbic acid in alloxan diabetic rats. *Comparative Biochemistry and Physiology*, 124: 233- 237.
- Gauthaman K and Adaikan PG (2008) The hormonal effect of *Tribulus Terrestris* and role its role in the management of erectile dysfunction- an evaluation using primates rabbit and rats. *Phytomedicine*, 15 (1): 44- 54.
- Ghosh D, Das UB, Misro M (2002).Protective role of alpha- tocopherol- succinate in cyclo-phosphamide induced testicular gametogenic steroidogenic disorders: a correlative approach to oxidative stress. *Free Radical Research*, 36: 1199-1208.
- Harbone JB (1998) Methods of extraction and isolation. In: *Phytochemical methods: A guide to modern technique of plant analysis*. 4<sup>th</sup> edition, London: Chapman and Hall, pp: 61.
- Isidori AM, Pozza C, Gianfrilli D, Isidori A (2006) Medical treatment to improve sperm quality. *Journal of Reproductive Biomedicine*, 12: 704- 714.
- Kosif R, Gulhan A, Oztekin A (2008) Microscopic examination of placenta of rats prenatally exposed to *Aloe barbadensis*: A preliminary study, *International Journal of Morphology*, 2: 275- 280.
- Kujo S (2004) Vitamin C: basic metabolism and its function as an index of oxidative stress. *Current Medicinal Chemistry*, 11: 1041- 1064.
- Latha PG and Panikkar KR (1990) Inhibition of Chemical carcinogenesis by *Psoralea corylifolia* seeds. *Journal of Ethnopharmacology*, 68: 295-298.
- Luck MR, Jeyaseelan I, Scholes RA (1995) Ascorbic acid and fertility. *Biology of Reproduction*, 52: 262- 266.
- Mahajan BK (1997) *Methods in Biostatistics for Medical and Research Worker*. 6<sup>th</sup> edition, New Delhi: JAYPEE Brothers Publication, pp: 215.
- Morels A (1996) Androgen supplementation in practice: the treatment of erectile dysfunction associated with hypotestosteronemia. In Oddens BJ, Vermeulen A, eds. *Androgens and aging male*. London: Parthenon Publishing Group, pp. 233.
- Mosher WD and Pratt WF (1991) Fecundity and infertility in the United States: Incident and trend. *Journal of Fertility and Sterility*, 56:192- 193.
- Mujumdar SS, Tsuruta J, Griswold MD, Bartke A (1995) Isolation and culture of sertoli cells from the testes of adult Siberian Hamsters: Analysis of protein synthesized and secreted by sertoli cells cultured from Hamsters raised in a long or a short photoperiod. *Biology of Reproduction*, 52: 658- 666.
- Mukhallad AM, Mohamad MJM, Dradka H (2009) Effects of black seeds (*Nigella sativa*) on spermatogenesis and fertility of male rats. *Res J Med Med Sci*, 4:386-390.
- Mukherjee and Kanai L (1988) *Medical Laboratory Technology. A procedure manual for routine diagnostic tests*. 2<sup>nd</sup> edition.
- OECD (2001) *Guidance for testing of chemicals, Acute Oral Toxicity- Acute Toxic Class Method*, 17: 423.
- Padashetty SA and Mishra SH (2007) Aphrodisiac studies of *Tricholepis glaberrima* with supportive action from antioxidant enzyme. *Pharmaceutical Biology*, 45: 580- 586.
- Ratnasooriya WD. and Fernando TSP (2008). Effect of black tea brews of *Camellia sinensis* on sexual competence of male rats. *Journal of Ethnopharmacology*, 118:373-377.

- Salem MH, Kamel KI, Yousef MI, Hassan GA, EL- Nouty FD (2001) Protective role of ascorbic acid to enhance semen quality of rabbits treated with sublethal doses of aflatoxin B1. *Toxicology*, 162: 209- 218.
- Sarawat AK and Chand S (2001) Continuous somatic embryogenesis and plant regeneration from hypocotyl segments of *Psoralea corylifolia* Linn. An endangered and medicinally important Fabaceae plant. *Current Science*, 18: 1328-1331.
- Sharma AR, Verma, Ramteke P (2009) Antibacterial activity of some medicinal plants used by tribals against causing pathogens. *World Applied Sciences Journal*, 7: 332-339.
- Shukla VN and Khanuja SPS (2004) Chemical, Pharmacological and botanical studies on *Pedaliu murex*. *Journal of Medicinal Aromatic Plant Science*, 26: 64- 96.
- Singh S and Gupta YK (2011) Aphrodisiac activity of *Tribulus terrestris* Linn. in experimental models in rats. *Journal of Men's Health*, 8: 575-577.
- Tajuddin, Ahmad S, Latif A, Ahmad IQ, Yusuf AKM (2005) An experimental study of sexual function improving effect of *Myristica fragrans* Houtt (nutmeg). *BMC Complementary and Alternative Medicine*, 5: 16-14.
- Taylor GT, Weiss J, Frechmann T, Heller J (1985) Copulation induces an acute increase in epididymal sperm numbers in rats. *Journal of Reproduction and Fertility*, 73(2): 323- 327.
- Thakur M and Dixit VK (2006) Effect of *Chlorophytum borivilianum* on androgenic sexual behaviour of male rats. *Indian Drugs*, 43: 300- 306.
- Thakur M and Dixit VK (2007) Aphrodisiac activity of *Dactylorhiza hatagirea* (D. Don) Soo in male albino rats. *Evidence Based Complementary Alternative Medicine*, 4: 29- 31.
- Thimmaiah SR (2004) Standard methods of biochemical analysis. 2<sup>nd</sup> edition, New Delhi: Kalyani Press.
- Tietz NW (1995) Clinical Guide to Laboratory Tests. 3rd edition, Philadelphia, USA: WB Saunders Company.
- Uotila M, Ruoslathi E, Envall E (1981) Two-site sandwich enzyme immunoassay with monoclonal antibodies to human alphafetoprotein. *Journal of Immunological Methods*, 42: 11-15.
- Watcho P, Donfack MM, Zelefack F, Nguelefack TB, Wansi S, *et al* (2005) Effects of the hexane extract of *Mondia whitei* on the reproductive organ of male rat. *African Journal of Traditional Complementary Alternative Medicine*, 2: 302- 311.
- World Health Organization (1999) WHO laboratory manual for the examination of human semen and semen- cervical mucus interaction. 4<sup>th</sup> edition, Cambridge University Press, NewYork.
- Yang NJ, Kaphle K, Wang P, Jang D, Wa L, Lin J (2004) Effect of aqueous extracts of "Betel Quid" and its constituents on testosterone production by dispersed mouse intestinal cell. *American Journal of Chinese Medicine*, 32:705-715.
- Zarrow MX, Yochim JM, McCarthy JL (1964) Experimental Endocrinology: A Sourcebook of Basic Techniques. Academic Press, New York, pp. 23-27.

© 2013| Published by IJLSCI

**Cite this article as:** Dabhadkar DK, Zade VS, Dhore MM and Patil SS (2013) The effects of chloroform extract of *Psoralea corylifolia* seed on reproductive abilities of male albino rats. *Int. J. of Life Sciences*, 1(2):133-142.

**Source of Support:** Department of Science and Technology, Government of India  
**Conflict of Interest:** None declared